

needed, additional biological and radiologic examinations were performed. Clinical evaluation of each patient, at baseline and during treatment, was always performed by the same clinician. The main criterion of IFX efficacy in our patients was the static physician global assessment tool. Disease activity and severity were also assessed using the Hurley score, visual analog pain scale, and Dermatology Life Quality Index (Table I).²⁻⁴

Thirteen patients were enrolled and no adverse events were observed, except for 1 patient who developed paradoxical pustular psoriasis. An objective response was observed in 9 patients. We observed worsening of disease in 4 patients, who tended to have the highest Dermatology Life Quality Index score (Table I). Two patients were underdosed with drug trough levels less than 2 µg/mL and 1 of them developed antibodies against IFX (Table I). High baseline levels of IL-6 and hs-CRP were predictive of nonresponse to IFX ($P = .0168$ and $.0112$, respectively, using Mann-Whitney test) (Table II). Inversely, all patients with IL-6 level below 5 (area under the curve 0.9167; 95% confidence interval 0.7423-1.091; $P = .02064$) responded to the treatment. The clinical severity score at baseline, IL-1 β , and TNF- α serum levels did not appear as a good predictive markers of response to IFX-therapy (Table II). A correlation was observed between serum levels of hs-CRP and IL-6 ($r = 0.79$, $P = .0005$ using the Pearson correlation test). No similar data were observed with hs-CRP/IL-1 ($r = 0.1$, $P = .74$), hs-CRP/TNF ($r = 0.12$, $P = .65$), or IL-1/IL-6 ($r = 0.01$, $P = .73$). We did not observe any correlation between response to treatment and kinetics of IL-6, hs-CRP, IL-1 β , and TNF- α , with no significant change in their levels during IFX therapy (data not shown).

These results suggest that initial levels of hs-CRP and IL-6 are potential response markers for IFX treatment in HS. Additional studies are needed to determine whether these markers can predict the response to other TNF inhibitors. As there are multiple confounding factors when using CRP levels,⁵ it is possible that IL-6 has greater reliability for predicting the response to treatment in patients with HS.

Henri Montaudié, MD,^a Barbara Seitz-Polski, MD, PhD,^b Aurore Cornille, MSc,^b Sylvia Benzaken, MD,^b Jean-Philippe Lacour, MD,^a and Thierry Passeron, MD, PhD^{a,c}

Department of Dermatology^a and Immunology Laboratory,^b University Hospital of Nice; and Institut National de la Santé et de la Recherche Médicale

(INSERM), U1065, Centre Méditerranéen de Médecine Moléculaire, Team 12,^c Nice, France

Drs Montaudié and Seitz-Polski contributed equally to this letter.

Funding sources: None.

Disclosure: Dr Passeron has received honoraria and travel expenses from Abbvie, GSK, Janssen, MSD, Novartis, and Pfizer. Dr Montaudié has received honoraria from Pfizer. Drs Seitz-Polski, Benzaken, and Lacour, and Ms Cornille have no conflicts of interest to declare.

Correspondence to: Thierry Passeron, MD, PhD, 151 route de Saint Antoine de Ginestière, Hôpital Archet 2, 06200 Nice, France

E-mail: thierry.passeron@unice.fr

REFERENCES

- Ingram JR, Woo PN, Chua SL, et al. Interventions for hidradenitis suppurativa: a Cochrane systematic review incorporating GRADE assessment of evidence quality. *Br J Dermatol*. 2016;174:970-978.
- Revuz J. Clinical evaluation of the severity of hidradenitis suppurativa. *Ann Dermatol Venereol*. 2015;142(12):729-735.
- Grant A, Gonzalez T, Montgomery MO, Cardenas V, Kerdel FA. Infliximab therapy for patients with moderate to severe hidradenitis suppurativa: a randomized, double-blind, placebo-controlled crossover trial. *J Am Acad Dermatol*. 2010;62(2):205-217.
- Finlay AY, Khan GK. Dermatology Life Quality Index (DLQI)-a simple practical measure for routine clinical use. *Clin Exp Dermatol*. 1994;19:210-216.
- Pepys MB, Hirschfield GM. C-reactive protein: a critical update. *J Clin Invest*. 2003;111(12):1805-1812.

<http://dx.doi.org/10.1016/j.jaad.2016.08.036>

Intradermal injection of autologous platelet-rich plasma for the treatment of vulvar lichen sclerosus



To the Editor: We designed a pilot study to evaluate the efficacy and safety of autologous platelet-rich plasma (PRP) injections for the treatment of vulvar lichen sclerosus (VLS). After IRB approval was obtained, 15 patients with biopsy proven VLS received 2 separate treatments of PRP separated by 6 weeks. Each treatment consisted of 5 mL of autologous PRP (Magellan Autologous Platelet Separator System, Arteriocyte Medical Systems) injected subdermally and intradermally. A repeat biopsy was performed 6 weeks after the second PRP injection. Patients were not permitted to use additional medications during the trial. The primary efficacy variable, as measured by 2 masked dermatopathologists, was the change in inflammation between the pre- and post-treatment biopsies.

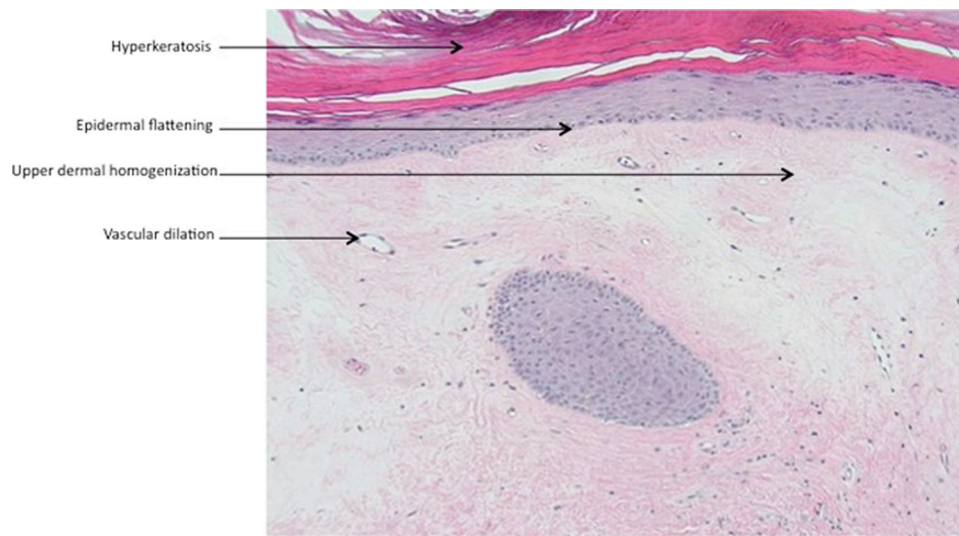


Fig 1. Pretreatment biopsy demonstrates hyperkeratosis with flattening of the epidermis, homogenization of the upper dermis with vascular dilation, and focal inflammation in the mid-dermis. (Hematoxylin-eosin stain; original magnification $\times 100$.)

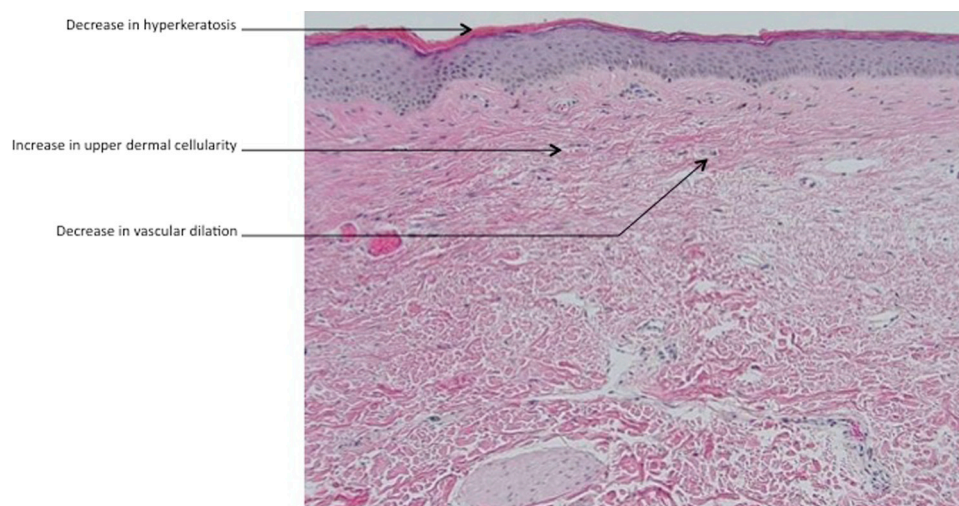


Fig 2. Post-treatment biopsy shows a marked decrease in hyperkeratosis and a decrease in vascular dilation and inflammation, as well as a return of upper dermal cellularity. (Hematoxylin-eosin stain; original magnification $\times 100$.)

Secondary endpoints included changes from baseline in pruritus and vulvar burning using visual analogue scales (VAS) and change in Investigator's Global Assessment (IGA) of the severity of the disease (0 to 3 scale). Twelve of the 15 participants completed the protocol, 2 participants were lost to follow-up before the second PRP treatment, and another refused post-treatment biopsy. Of the 12 patients who completed the protocol, the dermatopathologists determined that 7 had decreased inflammation on their post-treatment biopsies (Figs 1 and 2), 3 had no change, and 2 had

a "minimal" increase in inflammation. A repeated measures ANOVA showed that these results were statistically significant: $F(1,11) = 6.81$, $P = .024$. A paired-sample t -test comparing the pre- and post-treatment IGA scores showed a statistically significant difference: pre-treatment ($M = 2.67$, $SD = 0.49$) and post-treatment ($M = 1.83$, $SD = 0.83$); $t(11) = 3.4578$, $P = .0054$. Changes in subjective VAS scores for pruritus and burning were not statistically significant. No adverse reactions were reported except transient discomfort and bruising at the biopsy and injection sites.

The effectiveness of PRP is based on its high level of growth factors such as PDGF, TGF- β , and EGF. These growth factors are important in modulating mesenchymal cell proliferation, and extracellular matrix synthesis during healing. PRP has shown to be effective at propagating new healthy tissue growth in a wide range of medical conditions such as diabetic foot ulcers, venous stasis ulcers, and tendonopathy.¹⁻³ The vast majority of published literature shows that autologous PRP has minimal risk of scar tissue formation or serious adverse events (SAEs). Previously, 1 study examined injections of a combination of PRP and fat-derived mesenchymal cells in 15 women with VLS.⁴ The authors reported that “all patients reported total disappearance of pain and symptoms.” However, a significant limitation of the study was that 2 concurrent interventions were performed, which limited the ability to determine which intervention was efficacious or necessary. In addition, no objective measures of efficacy were used. In contrast, our study used an objective endpoint (decrease in histopathologic inflammation) measured by masked evaluators. Limitations of this study are the small sample size, lack of placebo control, and short-term follow-up. However, the statistically significant results suggest that PRP decreased histopathologic inflammation in women with VLS without the potential side effects associated with topical or systemic immunomodulators.

Andrew T. Goldstein, MD,^a Michelle King, MSc,^b
Charles Runels, MD,^c Meghan Gloth, MD,^d and
Richard Pfau, MD^e

George Washington University School of Medicine and Health Sciences,^a Washington, DC; Nova Southeastern University College of Osteopathic Medicine,^b Fort Lauderdale, Florida; Private practice,^c Fairhope, Alabama; University of Maryland Medical Center, Department of Pathology,^d Baltimore, and Anne Arundel Dermatology,^e Annapolis, Maryland

Funding Sources: None.

Conflicts of interest: None declared.

Correspondence to: Andrew T. Goldstein, MD,
George Washington University School of Medicine and Health Sciences, Washington, DC

E-mail: obstetrics@yahoo.com

REFERENCES

1. Sarvajnamurthy S, Suryanarayan S, Budamakuntala L, et al. Autologous platelet rich plasma in chronic venous ulcers: study of 17 cases. *J Cutan Aesthet Surg*. 2013;6:97-99.
2. Yotsu RR, Hagiwara S, Okochi H, et al. Case series of patients with chronic foot ulcers treated with autologous platelet-rich plasma. *J Dermatol*. 2015;42:288-295.
3. Wesner M, Defreitas T, Bredy H, et al. A pilot study evaluating the effectiveness of platelet-rich plasma therapy for treating degenerative tendinopathies: a randomized control trial with synchronous observational cohort. *PLoS One*. 2016;11:e0147842.
4. Casabona F, Priano V, Vallerino V, et al. New surgical approach to lichen sclerosus of the vulva: the role of adipose-derived mesenchymal cells and platelet-rich plasma in tissue regeneration. *Plast Reconstr Surg*. 2010;126:210e-211e.

<http://dx.doi.org/10.1016/j.jaad.2016.07.037>

Localized hypohidrosis is an unrecognized sequela of herpes zoster



To the Editor: The association of localized hypohidrosis and herpes zoster (HZ) has not been described except in Horner's syndrome.¹ However, recent reports describing herpetic syringitis² and immunohistochemical detection of varicella zoster virus (VZV) major envelope glycoprotein (gE) antigen in eccrine units³ suggest the possibility of sweat gland/duct involvement of HZ.

We evaluated sweating responses to thermal stimulus or acetylcholine injection in the involved and uninvolved dermatomes at various time points after onset of HZ by using the impression mold technique (IMT), which allows an accurate quantification of each sweat gland/duct activity to sweat.⁴ In this test, sweat droplets are visualized as small holes corresponding to the sweat pores. The study protocol involved measurements on two different occasions: the acute (≤ 10 days after onset) and resolution (> 10 day from onset of HZ) stages. All test results in patients with HZ were compared with control values obtained from healthy volunteers ($n = 12$). Mean age of HZ patients in the acute ($n = 9$) and resolution ($n = 10$) stages were 50.1 ± 7.8 years and 46.1 ± 8.6 years, respectively. Involved sites included trunk and extremities. This study was approved by the Institutional Review Board at Kyorin University.

The results of the IMT are given in Fig 1. Significant sweating disturbance was detected in the involved dermatome of HZ after thermal stimulus regardless of the stage, but not in the uninvolved dermatome. Sweating disturbance in the involved dermatome of HZ was also detected after acetylcholine injection in the resolution stage, but not in the uninvolved dermatome.

Immunohistochemistry revealed high levels of dermcidin (DCD) peptides, sweat specific components, in the cytoplasm and luminal membranes of